



# HUNTINGTON DENTAL GROUP WILLIAM T MYERS DDS

1306 Commerce Avenue Huntington, WV 25701  
304-697-7190

#031

## Featured Topics



Radiographs - X-Rays

## Oral CDx Testing

Now, for the first time, dentists have a tool that allows them to easily and painlessly test for oral cancer.

This novel testing tool is called **OralCDx**, a system that combines a painless brush biopsy, which is taken by the dentist in the office, and advanced computer analysis. **Oral CDx** allows dentists to test for early signs of oral cancer, which may have previously gone undiagnosed.

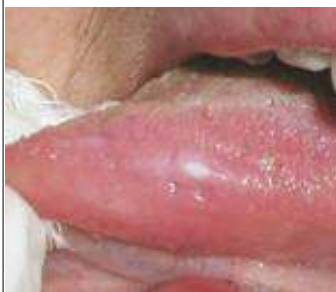Your dentist has a **painless new way to test** even the **tiny spots** in your mouth for **oral cancer.**

OralCDx addresses a significant diagnostic dilemma for dentists. In the early stages, oral cancer can be difficult to detect. It usually begins as a small red or white spot or sore anywhere in the mouth. On visual inspection it can be indistinguishable from common, harmless spots or sores that many people have in their mouth at some time. Until OralCDx, the only reliable way to know which spots or sores were dangerous required referral to a surgeon to have them removed for testing in a procedure called a scalpel



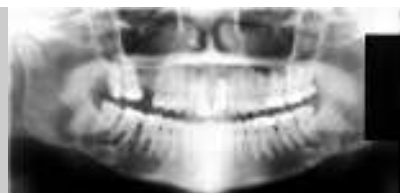The problem has been that early stage oral cancer lesions look like benign mouth lesions, even to the vigilant dentists. By the time a lesion becomes an obviously and visibly cancerous lesion, succession treatment is many times much more difficult with less successful results.

About 8,000 Americans die of oral cancer each year. Nearly 30,000 new cases are diagnosed annually, and only 53 percent of all oral cancer victims are still alive five years after diagnosis. But among those in whom the disease -- which is most common among tobacco users and heavy drinkers and is more common among men, people over 40 and African Americans--is caught early, five-year survival rates soar to 88 percent.....



A suspected white oral lesion on the side of the tongue. A painless lesion that is easily tested with the OralCDx system.

This newsletter a service of Huntington Dental Group. To be added to the HDG newsletter & e-mail list, send request to: [news@hdgww.com](mailto:news@hdgww.com) or call 304-697-7190



## Dental X-Rays or Radiographs -

Dental X-rays are used to take pictures of the teeth, bones, and surrounding soft tissues. X-ray pictures can show tooth decay, hidden dental structures, and bone




# HUNTINGTON DENTAL GROUP

## Early signs of oral cancer:

- Often starts as a tiny, unnoticed white or red spot or sore anywhere in the mouth

### Other signs of oral cancer can include:

- a sore that bleeds easily or does not heal
- a color change of the oral tissues
- a lump, thickening, rough spot, crust or small eroded area
- pain, tenderness, or numbness anywhere in the mouth or on the lips

 represents a breakthrough in oral cancer detection, a test that will allow you and your dentist to improve the prognosis of a disease that has remained unchanged for the last

## Misconceptions and Facts About Oral Cancer:

**MISCONCEPTION:** Many people don't die from oral cancer

**FACT:** Oral cancer affects more than 30,000 Americans each year claiming over 8,000 lives as compared to melanoma and cervical cancer, which account for approximately 8,000 and 5,000 deaths per year, respectively.

**MISCONCEPTION:** Only those people who smoke and drink alcoholic beverages regularly are at risk for developing oral cancer.

**FACT:** Although most often associated with smoking, over 25 percent of oral cancer victims have not used tobacco, and have no other known risk factors.

**MISCONCEPTION:** Common sores in the mouth are little cause for concern.

**FACT:** In the majority of the cases, common sores are usually benign, but they should be tested for abnormalities as a safeguard. According to published studies, between five and 15 percent of adults have a benign-appearing white or red sore in their mouth that could be pre-cancerous. It is crucial to identify these lesions in the earliest, most curable stage.

**MISCONCEPTION:** Oral cancer examinations are painful.

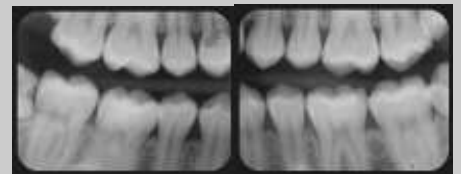
**FACT:** If a dentist identifies a suspicious lesion in the mouth, he/she can now use OralCDx, a new, painless brush biopsy system that is performed on lesions to determine if there are any potentially cancerous cells present.

**MISCONCEPTION:** Oral cancer lesions are easy to identify.

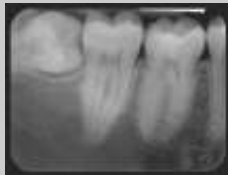**FACT:** In the earliest, most treatable stage, oral precancerous and cancerous lesions appear similar to harmless, small white or red sores. Therefore, it is very difficult for a dentist to visually identify which lesions are harmful. If not detected early, these benign-looking but dangerous sores can progress to more advanced, malignant stages. OralCDx can identify oral lesions that are potentially dangerous, even when they do not look suspicious.

## The following types of dental X-rays are commonly used.

- Bitewing X-rays use the least amount of radiation and show the upper and lower back teeth in a single view. They are used to detect decay between the teeth and to show how well the upper and lower teeth line up. They also show bone loss that usually indicates the presence of severe gum disease or a dental infection.



- Periapical X-rays show the entire tooth, from the exposed crown to the end of the root and the bones that support the tooth. These X-rays are used to detect dental problems below the gum line or in the jaw, including the presence of impacted 'wisdom teeth' (as pictured here).



- Panoramic X-rays provide a broad view of the jaws, teeth, sinuses, nasal area, and temporomandibular (jaw) joints. These X-rays reveal problems such as impacted teeth, bone abnormalities, cysts, solid

